

Immunolocalisation of Ki-67 in Different Periodontal Conditions.

Nagappa G,^{*} Jetty Kuttickal,[†] Shivanand Aspalli,[‡] Anupama.M,[§] Reetika Gaddale,^{||} Mukta.V.Sanikop[¶]

^{*} Reader, [†] Postgraduate, [‡] Professor And Head Of Department, [§] Reader, ^{||} Senior Lecturer
[¶] Postgraduate, Department Of Periodontics And Oral Implantology, A.M.E's Dental College & Hospital,
Bijangera Road, Raichur – 584103, Karnataka, India

A one-sentence summary describing the key finding(s) from the study – Ki-67 expression found to be highest in chronic periodontitis followed by chronic gingivitis and healthy control.

Abstract

Background: Ki-67 is a non-histone nuclear protein which is expressed in proliferating cells, during all the active phases of the cell cycle. Increased Ki-67 expression has been seen in several inflammatory and malignant conditions like diabetes, rheumatoid arthritis, atherosclerosis, pancreatitis and squamous cell carcinoma.

Aim: The aim of the present study is to analyze the expression of Ki-67 in gingival tissues in subjects with healthy periodontium, chronic gingivitis and chronic periodontitis by immunohistochemistry.

Materials and Methods: Gingival biopsies (n = 30) were obtained from clinically healthy gingiva (n = 10), chronic gingivitis (n = 10), and chronic periodontitis (n = 10). The expression of Ki-67 was evaluated immunohistochemically. Statistical analysis used: Mean and standard deviation were estimated for the gingival tissue extract sample for each study group. Mean values were compared between different study groups by, one way ANOVA, post hoc analysis. In this study P < 0.05 was considered as the level of significance.

Results: The mean number of Ki-67 positive cells/field were highest in chronic periodontitis (69.27 cells/field) followed by chronic gingivitis (37.23 cells/field) and healthy control (10 cells/field). Statistical significant difference was observed when the mean Ki-67 positive cells were compared between different groups.

Conclusions: Ki-67 was maximally expressed in chronic periodontitis patients followed by chronic gingivitis and healthy controls. The findings of this study also help us to understand the role of Ki-67 in the pathogenesis of chronic periodontitis.

Keywords: Ki-67, periodontitis, immunolocalisation.

I. Introduction

Immunohistochemistry (IHC) is the localization of antigens or proteins in tissue sections by the use of labeled antibodies as specific reagents through antigen-antibody interactions usually visualized by a fluorescent marker. One of the best markers that can be used to analyze cell proliferation in healthy and diseased tissues is Ki-67. The Ki-67 antigen was originally identified by a German group in the early 1980s, by use of a mouse mAb against a nuclear antigen from a Hodgkin's lymphoma-derived cell line. This non-histone protein was named after the researcher location, Ki for Kiel University, Germany, with the 67 label referring to the clone number on the 96-well plate.¹

Ki-67 is a non-histone nuclear protein and is expressed in proliferating cells, during all the active phases of the cell cycle.² Ki-67 antibodies recognize a human nuclear antigen which is absent in G0 (resting) phase and expressed during the G1, S, G2 and M phases of the cell cycle and is a good proliferative marker as it stains strongly in paraffin sections.¹ It denotes a nuclear protein forming part of a DNA replicase complex and the expression reaches a peak in G2 and mitotic phase and rapidly degrades after mitosis.³ During interphase the Ki-67 can be exclusively detected within the cell nucleus, whereas in mitosis most of the protein is relocated to the surface of the chromosomes. The monoclonal antibody Ki-67 is used to demonstrate the expression of this nuclear protein. The antibody binds to its specific-antigen present in the nuclei of proliferating cells, staining them and highlighting all cells that have entered the cell division cycle. Immunohistological detection of these proteins represents a useful marker of the proliferative status of the gingival tissue samples in health and disease.

Increased Ki-67 has been seen in several inflammatory and malignant conditions like diabetes, rheumatoid arthritis, atherosclerosis, pancreatitis, and squamous cell carcinoma.² Chronic inflammatory reaction could act as stimulators causing epithelial proliferation.⁴ The inflammatory intensity is not only related to an increased amount of antigen in the lesion, but also to an exacerbated response of the defence mechanisms of the individuals.⁵ As chronic periodontitis is also an inflammatory condition, Ki-67 is measured by

immunohistochemistry in healthy and diseased periodontium so as to understand the role of the cell cycle in resolution of periodontal inflammation which is a salient feature in the pathogenesis of chronic periodontitis.

II. Aims & Objectives

1. To analyse the expression of Ki-67 in gingival tissues by immunohistochemistry in subjects with healthy periodontium, chronic gingivitis and chronic periodontitis.
2. To understand its role in the pathogenesis of periodontal disease.

III. Materials & Method

Patients with age ranging between 18 to 55 years were selected. Both male and female patients were included in the study. Total 30 patients attending the outpatient Department of Periodontics and Oral Implantology, were selected based on the inclusion and exclusion criteria. A written and verbal informed consent was taken from all the patients before the start of the study.

The total number of subjects which were to be included in the study were determined based on discussion held with the biostatistician, in which he was informed about the various parameters involved in the study. The study project was reviewed by the ethical committee board of A.M.E's Dental College and Hospital and Research Centre, Raichur, Karnataka. After seeking approval from the committee, study project was envisaged.

3.1 Study Group:

After the preliminary screening of individuals, 30 subjects were included in the study with age range of 18 to 55 years. The subjects were divided into three groups

- Group I (control) includes 10 healthy subjects.
- Group II includes 10 patients with gingivitis.
- Group III includes 10 patients with chronic periodontitis.

3.2 Selection Criteria:

The following inclusion and exclusion criteria were used for the selection of patients.

3.2.1 Inclusion Criteria:

1. Healthy group – clinically healthy gingiva, ≤ 20 % bleeding sites, no attachment loss, probing depth < 3 mm and no radiographic evidence of bone loss.
2. Chronic gingivitis group - ≥ 20 % bleeding sites, no attachment loss, probing depth < 3 mm and no radiographic evidence of bone loss.
3. Chronic periodontitis group - probing depth of ≥ 5 mm, loss of attachment ≥ 2 mm, bleeding on probing, radiographic evidence of ≥ 3 mm bone loss.

3.2.2 Exclusion Criteria:

1. Patients with history of any systemic diseases such as diabetes, hypertension etc.
2. Patient under any antibiotics or anti-inflammatory drugs in the past 6 months.
3. Patients who underwent any periodontal therapy in the past 6 months.
4. Pregnant or lactating women.

3.3 Investigations:

1. Blood investigations.
2. Intra-oral periapical radiographs (IOPA).

3.4 Study Design:

A case control study was carried out to evaluate the expression of Ki-67 in gingival tissues in subjects with healthy periodontium, chronic gingivitis and chronic periodontitis. Total 30 patients were included in the study. The subjects were divided into three groups.

- Group I (control) includes 10 healthy subjects.
- Group II includes 10 patients with chronic gingivitis.
- Group III includes 10 patients with chronic periodontitis.

3.5 Clinical Assessment:

William's periodontal probe was used to measure clinical parameters. Clinical parameters assessed were

- a. Plaque index (Sillness and Loe)
- b. Gingival index (Loe and Sillness)
- c. Sulcus bleeding index (Muhlemann. H.R)
- d. Probing Pocket Depth.
- e. Clinical Attachment Level.

3.6 Sample Collection and Processing

1. Control gingival samples were obtained from systemically healthy patients undergoing orthodontic extractions.
2. Chronic gingivitis samples were obtained from patients undergoing gingivectomy in the Department of Periodontics.
3. Chronic periodontitis samples were obtained from patients undergoing extraction of periodontally involved teeth.

A portion of papilla was excised, washed in sterile saline to remove blood. It was fixed in 10% formalin for 24 hrs, following which it was dehydrated in 100% alcohol & then embedded in paraffin to prepare blocks. Two sections of 5 µm thickness were made for hematoxylin & eosin staining and for immunohistochemistry. Streptavidin - biotin method was used for detection of Ki-67 and immunoperoxidase labeling was done using streptavidin peroxidase for 10 minutes. In this process aminoethylcarbazole was used as chromogen for visualisation of binding. The sections were counterstained with mayer's hematoxylin and mounted for examination.

3.7 Immunohistochemical Kit:

Primary antibody: the primary antibody immunohistochemical kit was obtained from BioGenex laboratories, USA: rabbit polyclonal to Ki-67 0.2 mg/ml. The primary antibody was procured in concentrated form. Upon delivery it was placed in the eppendorf tube and centrifuged at 12,000 rpm for 20 seconds. It was then aliquot and diluted in the concentration of 1/100 using tris buffer saline and stored at a temperature of 2 - 4⁰ C, in the refrigerator as mentioned by the manufacturer. The supersensitive polymer horse raddish peroxidase kit was obtained from Biogenex Laboratories, USA.

3.8 Immunohistochemical Staining:

Immunostaining is a two-step process that involves the demonstration of antigens in tissues and cells first by the binding of an antibody to the antigen of interest and second, the detection and visualization of bound antibody by an enzyme chromogenic system.

3.9 Procedure:

Sections of tissue blocks were cut at 3-micron thickness, placed on poly -l-lysine coated slides for immunostaining and later placed for incubation for one hour at 50 degree centigrade over the slide warmer.

- I. **Deparaffinization and Rehydration:** The slides were deparaffinized with three changes of xylene for 30 minutes. Subsequently the slides were rehydrated with decreasing grades of alcohol i.e. absolute, 95%, 70% and 50% respectively. This was followed by washing sections under tap water for 20-30 minutes.
- II. **Application of peroxide block**
The slides were rinsed in distilled water and placed in 3% H₂O₂ for 10 minutes and rinsed again in distilled water for 15 minutes.
- III. **Antigen retrieval: HIER (heat induced epitope retrieval) using microwave oven method:** The slides were placed in plastic jar containing citrate buffer solution at a pH of 6 in a microwave at 92 degree centigrade for 10 minutes (800 watt power). Let it to cool up to room temperature.
- IV. The slides were rinsed in distilled water for 5 minutes.
- V. The slides were transferred in tris buffer (TBS) and washed twice for 5 minutes.
- VI. **Power block application:** Power block was added after wiping each slide gently for 10 minutes to block nonspecific reaction with other tissue antigens.
- VII. **Application of primary antibody:** The slides were incubated after draining with Ki-67 primary antibody which is diluted to a 1/100 concentration using TBS. The antibody was added on the slide with the

micropipette, so that the entire section was covered and incubated for 30 minutes. It was made sure that the slides were in level and the lid of the humidifying chamber was closed to prevent air drying.

- VIII. The slides were then washed thrice in TBS for 5 minutes.
- IX. Application of super enhancer reagent: Super enhancer was added after gently wiping the slides and incubated for 30 minutes at room temperature.
- X. The slides were washed thrice in TBS for 5 minutes.
- XI. Application of poly HRP reagent: Slides were blotted around sections and appropriate amount of poly HRP reagent was added to cover the specimens and incubated for 30 minutes.
- XII. The slides were washed thrice in TBS for 5 minutes.
- XIII. Application of substrate solution: DAB was added after drying the slides carefully and incubated the slides for 5 to 8 minutes. This produced a dark brown reaction end product.
- XIV. The slides were washed in distilled water.
- XV. Counter staining: The slides were immersed in a bath of haematoxylin for 10 minutes and rinsed with tap water for 10-20 minutes.
- XVI. Dehydration was done with increasing grades of alcohol 50 %, 70%, 95% and absolute alcohol respectively, transferred to three changes of xylene and mounted with DPX, a non-aqueous permanent mounting medium using cover slips.

Histomorphometric evaluation of stained sections: In healthy and gingivitis Ki-67 positive cells were seen in the basal layer of the epithelium. The hematoxylin eosin stained slides showed normal parakeratinized stratified squamous epithelium. The underlying connective tissue showed collagen fibers and blood vessels. In chronic periodontitis Ki-67 positive cells were seen in the basal and parabasal layer of the epithelium. The hematoxylin eosin stained slides showed parakeratinized proliferative epithelium. The underlying connective tissue showed intense chronic inflammatory cell infiltration predominantly lymphocytes, plasma cells, and dilated blood capillaries.

IV. Statistical analysis

Table 1: Comparison of demographic variables between the groups.

Category	Group 1	Group 2	Group 3
No of subjects	10	10	10
Age range (years)	20-35	17-28	28-60
Gender			
Males	5	6	5
Females	5	4	5
Mean plaque index	0.41	1.46	2.11
Mean Gingival index	0.30	1.47	2.0
Mean sulcular bleeding index	0.24	0.83	41.32

Mean and standard deviations were estimated for the gingival tissue extract sample for each study group. Mean values were compared between different study groups by, one way ANOVA, (Table 2) post hoc analysis. In this study $P < 0.05$ was considered as the level of significance.

Table 2 : Comparison of the Mean (SD) values among all the 3 groups using one way ANOVA test

Group	No of samples	Mean (SD)
Healthy periodontium	10	100.0 (68.5)
Chronic gingivitis	10	372.30 (128.1)
Chronic periodontitis	10	692.70 (231.5)
F value	-	35.349
P value	-	<0.001**

(p < 0.05 - Significant*, p < 0.001 - Highly significant**)

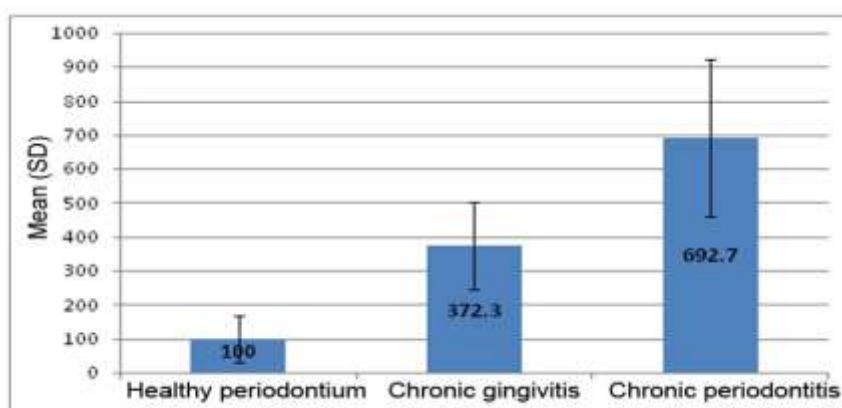


Figure 1: Comparison of the Mean(SD) values among all the 3 groups using one way ANOVA test.

V. Results

In the present study, a total of 30 clinically diagnosed, paraffin embedded tissue blocks including 10 cases of healthy controls, 10 cases of gingivitis and 10 cases of chronic periodontitis were selected and studied for the expression of Ki 67 which is a proliferative marker. The mean Ki-67 positive cells/field were highest in group III, i.e. chronic periodontitis (69.27 cells/field) followed by chronic gingivitis (37.23 cells/field) and healthy control (10 cells/field) (Table 3).

Table 3: Mean no of Ki-67 positive cells/field in various groups.

Group	N	Mean	Mean (SD)
1	10	10	100.0 (68.5)
11	10	37.23	372.30 (128.1)
111	10	69.27	692.70 (231.5)

Comparison between healthy and chronic gingivitis (-272.3), healthy and chronic periodontitis (-592.7) was statistically significant ($P = 0.002$, $P = .000$). Comparison between chronic gingivitis and healthy controls (272.3), chronic gingivitis and chronic periodontitis (-320.400) was statistically significant ($P = 0.002$, 0.000). Comparison between chronic periodontitis and healthy control (592.7), chronic periodontitis and chronic gingivitis (320.4) was statistically significant ($P = 0.001$) (Table 4).

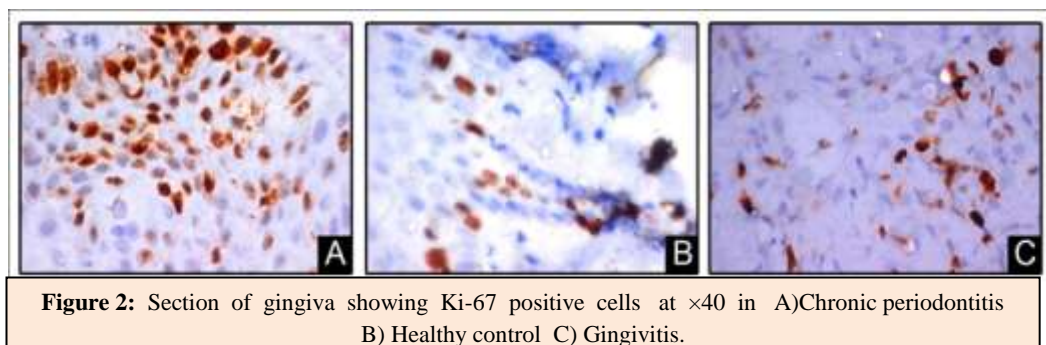
Table 4: Comparison of mean Ki-67 levels in different groups

Group		Mean Difference	Std error	Significance
Healthy periodontium	Chronic gingivitis	-272.300	70.568	.002
	Chronic Periodontitis	-592.700	70.568	.000
Chronic gingivitis	Healthy periodontium	272.3	70.568	.002
	Chronic Periodontitis	-320.400	70.568	.000
Chronic Periodontitis	Healthy periodontium	592.700	70.568	.000
	Chronic gingivitis	320.400	70.568	.000

Immunohistochemical reactivity of Ki -67

Immunohistochemistry of gingival tissue samples revealed positivity for Ki-67 in healthy, chronic gingivitis and chronic periodontitis. In healthy Ki-67 positive cells (fig: 2C) were seen in the basal layer of the epithelium. The hematoxylin eosin stained slides showed normal parakeratinized stratified squamous epithelium. The underlying connective tissue showed collagen fibers and blood vessels. In chronic gingivitis (fig: 2 B) Ki-67 positive cells were seen in the basal layer of the epithelium. The hematoxylin eosin stained slides showed orthokeratotic stratified squamous epithelium with features of basal cell hyperplasia and increased

melanin pigmentation. The underlying connective tissue showed collagen fibers, dilated blood capillaries and few inflammatory cells. In chronic periodontitis (fig: 2A) Ki-67 positive cells were seen in the basal and parabasal layer of the epithelium. The hematoxylin eosin stained slides showed parakeratinized proliferative epithelium. The underlying connective tissue showed intense chronic inflammatory cell infiltration predominantly lymphocytes, plasma cells, and dilated blood capillaries.



VI. Discussion

The present study was carried out to evaluate the expression of Ki-67 in gingival tissues in subjects with healthy periodontium, chronic gingivitis and chronic periodontitis. Ki-67 was maximally expressed in chronic periodontitis group (69.27 cells/field) followed by chronic gingivitis (37.23 cells/field) and healthy control (10 cells/field). The findings were in accordance with the study conducted by Penubolu Lakshmi et al in 2014 to analyze the difference in Ki-67 expression in smokers and non-smokers with healthy gingiva and chronic periodontitis, the lowest expression was seen in healthy (24.61 cells/field) followed by smokers without periodontitis (34.52), chronic periodontitis (44.05), and smoker with periodontitis (52.73).

In healthy gingival tissues Ki-67 positive cells were seen in the basal layer of the epithelium. The hematoxylin eosin stained slides showed normal parakeratinized stratified squamous epithelium. The underlying connective tissue showed collagen fibers and blood vessels. The findings were similar to an observational study by Kranti et al in 2015, where he analysed the immuno-histochemical expression of VEGF and Ki-67 in gingival samples of healthy and diabetes cases.⁶ The Ki-67 expression intensity was lowest in healthy individuals. This could be due to the fact that healthy gingiva is a somatic tissue with a normal turnover rate as compared to the other tissues of the body. Teresa et al have shown that normal Ki-67 expression in health is significantly lower compared to inflammation or cancerous state.⁷ In chronic gingivitis Ki-67 positive cells were seen in the basal layer of the epithelium. The hematoxylin eosin stained slides showed orthokeratotic stratified squamous epithelium with features of basal cell hyperplasia and increased melanin pigmentation. The underlying connective tissue showed collagen fibers, dilated blood capillaries and few inflammatory cells. This was similar to the study by Shadi et al where the Ki-67 expression in inflammatory gingivitis was similar to that in pyogenic granuloma.⁸ In chronic periodontitis Ki-67 positive cells were seen in the basal and parabasal layer of the epithelium, which was similar to the study by Penubolu Lakshmi et al.²

The hematoxylin eosin stained slides showed parakeratinized proliferative epithelium. The underlying connective tissue showed intense chronic inflammatory cell infiltration predominantly lymphocyte, plasma cells, and dilated blood capillaries. Ki-67 was maximally expressed in chronic periodontitis group. This was in accordance with study by Nagarakanti et al. where a significant increase in the proliferative marker (Ki-67) was found in periodontitis tissue samples versus healthy gingivas.⁹ They reported that the oral gingival epithelium should be the main source of this proliferation and differentiation. In the present study Ki-67 expression was highest in chronic periodontitis group. The reason for elevated Ki-67 levels in this group is due to effects of inflammation. Elevated NF- κ b levels have been shown in inflamed periodontal tissues by the study of Ambili et al.¹⁰ Also another study by Doger et al in psoriatic dermatitis cases has shown a positive correlation between NF- κ b, Ki-67 and dermal cell turnover rate.¹¹ May be the same mechanism of NF- κ b mediated Ki-67 expression could operate in the periodontitis samples compared to healthy patients.

On one hand, proinflammatory cytokines and mediators such as PGE2 are involved in periodontal tissue destruction but on the other hand elevated growth factor levels have also been seen in inflamed periodontal tissues compared to healthy tissues. In this regard Gurkan et al have shown that TGF- β levels have been found to be extensively elevated in chronic periodontitis.¹² TGF β can distinctly increase Ki-67 levels as

suggested by the study of Piekarska et al.¹³ The hallmark of periodontitis is the loss of connective tissue attachment to the tooth. Several cytokines have been reported to act as chemoattractants for migrating epithelial cells.¹⁴ It is possible that epithelial downgrowth is induced by some factor secreted from surrounding fibroblasts; this factor has been identified as HGF. HGF, also known as scatter factor (SF), is a heterodimeric protein secreted by cells of mesodermal origin.¹⁵ HGF induces a spectrum of biologic activities in epithelial cells, inducing mitogenesis, stimulation of cell motility, and the promotion of matrix invasion.¹⁶ It also is a morphogen¹⁷ and potent angiogenic factor.¹⁸ The existence of HGF in GCF in healthy and diseased gingiva was demonstrated and was found to be related positively to IL-1 β concentrations and to clinical parameters of disease progression. The study by Pradeep et al study showed that HGF concentration in GCF increased proportionally with progression of periodontal disease, which correlated directly with the stage of periodontal disease i.e gingival inflammation and CAL. HGF has also been shown to increase in chronic periodontitis.¹⁹ A higher level of HGF in GCF has been reported at periodontally compromised sites.²⁰ HGF can also modulate Ki-67 expression and the cell cycle as suggested by the study of Kanayama et al.¹⁹

VEGF is another important factor in the pathogenesis of periodontitis. It acts as a potent and pleiotropic inflammatory agent in periodontitis. It interacts with humoral factors that regulate bone homeostasis and bone development such as the recruitment of osteoblasts and osteoclasts. Bone formation and regeneration process are also linked to angiogenesis, a process in which VEGF is a major stimulant. Nevertheless, in periodontal tissues, angiogenesis seems to be important for the maintenance of tissue health and in periodontal diseases, VEGF is an important factor in the initiation and progression of gingivitis to periodontitis, promoting the expansion of the vascular network. Abberant angiogenesis is often associated with lesion formation in chronic periodontitis. The periodontal vasculature is profoundly affected during progression of periodontal disease. Early in the progression, the perivascular connective tissue become disrupted, the collagenous fibers are destroyed, creating spaces within the tissue which are quickly filled by inflammatory cells and loose connective tissue. Capillaries then proliferate into spaces created in the loose connective tissue by angiogenesis. Angiogenesis also contribute to severity of inflammation. VEGF expression may be induced by several inflammatory mediators including prostaglandin E2, IL-6 and IL-1. In addition VEGF expression is reported to be regulated by the oxygen concentration of tissues, with hypoxia inducing its expression.²¹ Booth et al. have suggested that VEGF was generally unregulated even in relatively healthy sites, probably either reflecting subclinical levels of inflammation/healing after the microbial assault, or revealing the presence of VEGF as a component of physiological angiogenesis in the gingival periodontal environment.²²

Another important growth factor involved in periodontal repair and wound healing is PDGF. This molecule has mitogenic effects on various cell types in the body. A study by Rollman et al has shown that PDGF gene transfer has a mitogenic effect on keratinocytes as seen by increased Ki-67 expression.²³ With regard to periodontal diseases an immunohistochemical study by Pinheiro et al has shown increased PDGF expression in inflamed gingiva rather than healthy gingiva.²⁴ This study gives an evidence of how locally generated PDGF in chronic periodontitis could modulate Ki-67 upregulation. Study by Silva et al concluded that the combination of chitosan and platelet derived growth factor-BB potently stimulated cell viability, cell proliferation and activation of the ERK1/2 pathway involved in cell proliferation.²⁵ These findings are in agreement with the concept that pocket epithelium plays an important role in pathogenesis of periodontal diseases probably by expressing biological mediators responsible for the attraction of defence cells to the site of infection i.e the periodontal pocket.²⁶ It is also possible that the production of these mediators could lead to expression of other molecules in underlying stroma, which in turn, would influence the proliferation of gingival epithelium and the remodelling of the periodontal connective tissues.

Proliferation, being an integral part of embryogenesis and wound repair, is an important parameter that need to be assessed in pathologies that involve aberrant healing. Periodontitis eventually occurs as a result of an imbalance between the invading micro organisms and the host response. The resultant inflammation causes an imbalance in the anabolic and catabolic processes in the periodontal tissues. Proliferative activity as assessed by the estimation of the cell cycle may reflect the state of the pathological as well as the healing processes in the periodontium. Ki-67 undergoes expression exclusively in proliferating cells. Synthesised at the beginning of the cell proliferation process, it is indispensable for cell division and it is effectively degraded at the end of the proliferative cycle. With the advent of newer technologies, accurate estimation of the cell cycle is made possible and such information may be used to device new therapeutic strategies.³⁰

VII. Conclusion

The study demonstrated highest mean Ki-67 positive cells/field in group III, i.e. chronic periodontitis followed by chronic gingivitis and healthy control. Inter-group comparison was statistically significant. In chronic periodontitis Ki-67

positive cells were seen in the basal and parabasal layer of the epithelium. There seems to be an increase in Ki-67 with increase in tissue proliferation. The surface area and the number of immunopositive cells increased with the severity of inflammation in the connective tissue. This could be explained on the assumption that chronic inflammatory reaction could act as stimulators causing epithelial proliferation. With the advent of newer technologies, accurate estimation of the cell cycle is made possible and such information may be used to device new therapeutic strategies. Discovery of various proliferation markers has enabled the detection of the hyperactive state of the epithelium and has been suggested to be of prognostic significance. Within the limitations of the present study, immunohistological detection of Ki-67 represents a useful marker of the proliferative status of the gingival samples in health and disease and helps us to understand its role in the pathogenesis of periodontal disease.

References

- [1]. W. Jonat, N. Arnold. Is the Ki-67 labelling index ready for clinical use? *Annals of Oncology* 2011;22:500–502.
- [2]. Preethi PL, Rao SR, Madapusi BT, Narasimhan M. Immunolocalization of Ki-67 in different periodontal conditions. *J Indian Soc Periodontol* 2014;18:161-5.
- [3]. Mehregan Darius, Mehregan David. Immunohistochemistry: A prognostic as well as diagnostic tool. *Seminars in cutaneous medicine and surgery* 1996;15:317-325.
- [4]. Mohamed S Ayoub, Houry M Baghdadi, Moataz El-Kholy. Immunohistochemical detection of laminin-1 and Ki-67 in radicular cysts and keratocystic odontogenic tumors. *BMC Clinical Pathology* 2011;11:4-6.
- [5]. Carrillo C, Peñarrocha M.A, Peñarrocha M, Vera-Sempere F, Peñarrocha. Immunohistochemical study of langerhans cells in periapical lesions correlation with inflammatory cell infiltration and epithelial cell proliferation. *Med Oral Patol Oral Cir Bucal* 2010;15 (2):335-9.
- [6]. Kranti K, Mani R, Elizabeth A. Immunoexpression of vascular endothelial growth factor and Ki-67 in human gingival samples: An observational study. *Indian J Dent* 2015;6:69-74.
- [7]. Teresa DB, Neves KA, Neto CB, Fregonezi PA, de Oliveira MR, Zuanon JA, et al. Computer assisted analysis of cell proliferation markers in oral lesions. *Acta Histochem* 2007;109:377-87
- [8]. Shadi Saghafi, Sakineh Amoueian, Mehdi Montazer, Roshanak Bostan. Assessment of VEGF, CD-31 and Ki-67 immunohistochemical markers in oral pyogenic granuloma: A Comparison with hemangioma and inflammatory gingivitis. *Iranian Journal of Basic Medical Sciences* 2011;14(2): 185-189.
- [9]. S.Nagarkanthi, S.Ramya, Praveen babu, K.V Arun, Sabitha. Differential expression of E-cadherin & cytokeratin 19 and net proliferative rate of gingival keratinocytes in oral epithelium in periodontal health and disease. *J Periodontol* 2007;78:2197-2202.
- [10]. Ambili R, Santhi WS, Janam P, Nandakumar K, Pillai MR. Expression of activated transcription factor NF- κ B in periodontally diseased tissues. *J Periodontol* 2005;76:1148-53.
- [11]. Doger FK, Dikicioglu E, Ergin F, Unal E, Sendur N, Uslu M. Nature of cell kinetics in psoriatic epidermis. *J Cutan Pathol* 2007;34:257-63.
- [12]. Gurkan A, Emingil G, Cinarcik S, Berdeli A. Gingival crevicular fluid transforming growth factor β 1 in several forms of periodontal disease. *Arch Oral Biol* 2006;51:906-12.
- [13]. Piekarska A, Piekarski J, Omulecka A, Szymczak W, Kubiak R. Expression of Ki-67, TGF- β 1 in liver tissue of patients with chronic liver diseases. *J Gastroenterol Hepatol* 2006;21:700-10
- [14]. Sato C, Tsuboi R, Shi CM, Rubin JS, Ogawa H. Comparative study of hepatocyte growth factor/scatter factor and keratinocyte growth factor effects on human keratinocytes. *J Invest Dermatol* 1995;104:958-963.
- [15]. Stoker M, Gherardi E, Perryman M, Gray J. Scatter factor is a fibroblast-derived modulator of epithelial cell mobility. *Nature* 1987;327:239-242.
- [16]. Weidner KM, Behrens J, Vandekerckhove J, Birchmeier W. Scatter factor: Molecular characteristics and effects on the invasiveness of epithelial cells. *J Cell Biol* 1990; 111:2097-2108.
- [17]. Montesano R, Matsumoto K, Nakamura T, Orci L. Identification of a fibroblast-derived epithelial morphogen as hepatocyte growth factor. *Cell* 1991;67:901-908.
- [18]. Bussolino F, DiRenzo MF, Ziche M, et al. Hepatocyte growth factor is a potent angiogenic factor which stimulates endothelial cell motility and growth. *J Cell Biol* 1992;119:629-641.
- [19]. Kanayama M, Takahara T, Yata Y, Xue F, Shinno E, Nonome K et al. Hepatocyte growth factor promotes colonic epithelial regeneration via Akt signaling. *Am J Physiol Gastrointest Liver Physiol* 2007;293:230-9.
- [20]. Rudrakshi C, Sreenivas, Mehta. A comparative evaluation of hepatocyte growth factor in GCF and saliva and its correlation with clinical parameters in patients with and without chronic periodontitis. *J Indian Soc Periodontol* 2011;15(2):147-51.
- [21]. Zoellner H, Hunter N. Vascular expansion in chronic periodontitis. *J Oral Pathol Med* 1991;20:433-7.
- [22]. Booth V, Young S, Cruchley A, Taichman NS, Paleolog E. Vascular endothelial growth factor in human periodontal disease. *J Periodontal Res* 1998;33:491-9
- [23]. Rollman O, Jensen UB, Ostman A, Bolund L, Gustafsdottir SM, Jensen TG. PDGF responsive epidermis formed from human keratinocytes transduced with the PDGF beta receptor gene. *J Invest Dermatol* 2003;120:742-9.
- [24]. Pinheiro ML, Feres-Filho EJ, Graves DT, Takiya CM, Elsas MI, Elsas PP, et al. Quantification and localization of PDGF in gingival of periodontitis patients. *J Periodontol* 2003;74:323-8.
- [25]. Silva D, Aranibia R, Tapia C, Acuna Rougier, Diaz-Dosque, Caecers, Martinez, Smith et al. Chitosan and platelet derived growth factor synergistically stimulate cell proliferation in gingival fibroblasts. *J Periodont Res* 2013; 48: 677-686.
- [26]. Kornman K, Page R, Tonetti M. The host response to the microbial challenge in periodontitis: assembling the players. *Perio* 2000 1997; 14:33-53.
- [27]. Yu X, Hsieh S, Bao W, Graves D. Temporal expression of PDGF receptors and PDGF regulatory effects on osteoblastic cells in mineralizing culture. *Am J Physiol* 1997;272: C1709-1716.
- [28]. Batista AC, Silva TA, Chun JH, Lara VS. Nitric oxide synthesis and severity of human periodontal disease. *Oral Dis* 2002;8:254-60.
- [29]. Hussain SP, He P, Subleski J, Hofseth LJ, Trivers GE, Mechanic L, et al. Nitric oxide is a key component in inflammation accelerated tumorigenesis. *Cancer Res* 2008;68:7130-6.
- [30]. KV Arun. Molecular biology of periodontium. 1st ed New Delhi Jaypee Brothers Medical Publishers 2010.